



## RESEARCH ARTICLE

### Histopathological and microbiological evaluation of uterus in repeat breeder cows shipped to slaughterhouse

Yunus Çakıcı<sup>1,a</sup>, Mehmet Aköz<sup>2\*,b</sup>

<sup>1</sup>Director of the Institute of Veterinary Control, Konya, Turkey

<sup>2</sup>Selcuk University, School of Health Services, Konya, Turkey

Received:19.07.2018, Accepted: 07.03.2019

\*makoz@selcuk.edu.tr

<sup>a</sup>ORCID: 0000-0003-3408-4858, <sup>b</sup>ORCID: 0000-0001-5835-7115

### Kesime sevk edilen repeat breeder ineklerde uterusların histopatolojik ve mikrobiyolojik değerlendirilmesi

Eurasian J Vet Sci, 2019, 35, 2, 71-78

DOI: 10.15312/EurasianJVetSci.2019.226

#### Öz

**Amaç:** Bu çalışmada, repeat breeder ineklerde endometritislerin histopatolojik muayene ile belirlenmesi ve endometritise neden olabilecek bakterileri araştırmak amaçlanmıştır.

**Gereç ve Yöntem:** Konya ilindeki mezbahalara kesim amacıyla getirilen 53 baş repeat breeder inekten ve 10 baş döl tutma problemi olmayan inekten alınan toplam 63 uterus örneği makroskopik, histopatolojik ve mikrobiyolojik yöntemlerle incelendi.

**Bulgular:** Çalışmada değerlendirilen 63 örneğin 22'sinde endometritis tespit edildi. Bunlardan 5'inde kataral endometritis, 5'inde purulent endometritis, 5'inde kronik nonpurulent endometritis, 6'sında kronik purulent endometritis ve 1'inde ise granülatöz endometritis tespit edildi. Mikrobiyolojik incelemede ise 11 uterusu bakteri izole edilirken, en çok *Streptococcus* spp. ve *Escherichia coli* izole edildi. Antibiyogram sonucuna göre ise identifiye edilen bakterilerin tümünün Amoksisilin/Klavulanik asit ve Florfenikol'e duyarlı olduğu tespit edildi. Bununla birlikte Penisilin G'ye karşı direncin arttığı belirlendi.

**Öneri:** İneklerde repeat breederin etiyolojisinde önemli faktörlerden biri olan endometritislerin belirlenmesinde histopatolojik muayenenin etkili olduğu görülmüştür. Uygun tedavi protokollerinin oluşturulmasında klinik muayene bulgularının, histopatolojik ve mikrobiyolojik bulgularla birlikte değerlendirilmesinin daha faydalı olacağı kanaatine varılmıştır.

**Anahtar kelimeler:** Endometritis, Histopatoloji, İnek, Mikrobiyoloji, Repeat breeder

#### Abstract

**Aim:** The purpose of this study is to determine endometritis in repeat breeder cows by histopathological examination and to investigate the bacteria that may cause endometritis.

**Materials and Methods:** A total of 63 uterus specimens taken from 53 repeat breeder cows brought to the slaughterhouses in Konya province for slaughtering and from 10 cows without any reproductive problem were examined by macroscopic, histopathological and microbiological methods.

**Results:** Histopathological examination showed that 22 out of 63 samples were diagnosed as endometritis. The types of the endometritis were determined which that 5 catarrhal endometritis, 5 purulent endometritis, 5 chronic nonpurulent endometritis, 6 chronic purulent endometritis and 1 granulosomatous endometritis were found. In the microbiological examination, it was found that while bacteria were isolated in 11 uteri, mostly *Streptococcus* spp. and *Escherichia coli* were isolated. According to the antibiogram results, all of the identified bacteria were determined to be susceptible to Amoxicillin/Clavulanic acid and Florfenicol. It is also found that isolated bacteria were found as increased penicillin G resistance.

**Conclusion:** It has been determined that endometritis is major causing factor in the etiology of repeat breeder in cows. Histopathological exams are key to diagnose endometritis causing repeat breeder. It has been concluded that when clinical findings are combined with histopathological and microbiological findings, the effective treatment protocol can be established.

**Keywords:** Endometritis, Histopathology, Cow, Microbiology, Repeat breeder



## Introduction

One of the most important factors affecting the sustainability of the dairy cattle farms and production is reproduction. There are many factors that adversely affect reproduction in dairy cattle farms and one of the most important factors is the Repeat breeder (RB) problem. Cows that giving birth, younger than 10 years of age, have estrus at regular intervals, clinically healthy and are not getting pregnant after breeding at least three times with a fertile bull or after performing artificial insemination even though are defined as RB (Aköz and Dinç 2001, Alaçam 2005, Saraswat and Purohit 2016).

Repeat breeder rates in dairy cattle farms are reported to be between 5-36% depending on variable factors (Purohit 2008, Perez-Marin et al 2012, Saraswat and Purohit 2016). Luperto Telli (2017) reported when the data received five-year average of five dairy cattle business in different regions in Turkey RBA rate varied between 4.8% and 21.38. He also emphasized that this ratio should be below 15% for a successful farms.

Two main reasons of RB having a multifactorial and complex etiology is the lack of the formation of fertilization and early embryonic deaths (Alaçam 2005, Saraswat and Purohit 2016). Other factors playing a role in etiology, play an important role in the emergence of RB problems by accompanying or leading to these two main causes (Maurer and Echternkamp 1985, Lafi and Kaneene 1988, Dinç 1990). These factors can be regarded as ovulation defects, genital canal pathologies, hormonal imbalances, genetic disorders, management and estrus detection deficiencies, insemination mistakes, sperm quality, infectious agents (bacteria, virus, and fungi) and endometritis (Alaçam 2005, Perez-Marin et al 2012, Saraswat and Purohit 2016). High milk yield, season, age, heat stress and immunological reactions are among the factors affecting the incidence of RB (Alaçam 2005, Purohit 2008).

It is reported that while the changes caused by the subclinical endometritis in the uterine environment have negative effects on embryonic life, subclinical endometritis sometimes due to the changing pH in the uterus environment prevents the formation of fertilization with its effects during the transportation of spermatozoon (Dinç 1990, Sheldon et al 2009, Ahmed and Elsheikh 2014).

Histopathologic examination, cytological examination, uterine culture and detection of molecular mediators in recent years are commonly used methods in the diagnosis of subclinical endometritis (Aköz and Dinç 2001, Azawi et al 2008, Chapwanya et al 2009, Cannazik and Polat 2015, Saraswat and Purohit 2016).

It was stated that microbiological examination used in the di-

agnosis of subclinical endometritis alone is not sufficient for diagnosis and more accurate results can be obtained when it is evaluated together with histopathologic findings (Polat 2008, Doğruer and Güler 2010).

By considering the etiologic factors in the treatment of repeat breeder cases, it is seen that the combined or individual use of hormone applications and intrauterine antibiotic and antiseptic applications are more preferred (Aköz and Dinç 2001, Perez-Marin et al 2012, Raval et al 2018).

The aim of the present study is to determine endometritis with histopathologic findings, microbiological agents that may cause endometritis and the efficiency of antibiotics in repeat breeder cows which were sent for slaughtering in Konya province

## Materials and Methods

### *Animal material*

The study was carried out between February and April 2017. The material of the study was consisted of 53 repeat breeder cows taken to to slaughter houses around Konya province. Also the uteri of 10 cows without any reproductive disorders was evaluated as the control group.

### *Clinical examination*

Clinically, the reproductive system of the animals were examined according to the abnormal vaginal discharge.

### *Postmortem examination*

Immediately after slaughtering, genital organs were macroscopically examined in terms of pathological structures (follicular cyst, luteinised cyst, tumor-like structures, atropy, etc.). The presence of CL and follicle on ovaries was examined in terms of ovarian activity.

### *Microbiological examination*

Samples were taken from cornu and corpus uteri cavities of the uteri collected after slaughtering with transport swabs with sterile cotton and transferred to the Bacteriology Laboratory of Konya Veterinary Control Institute in the cold chain for bacterial lawn. Swab samples were incubated at 37 ° C in aerobic and microaerophilic conditions for 48 hours with 7% sheep blood agar and MacConkey agar. Preparates prepared from isolated colonies were stained using Gram stain method (Bilgehan 1992). The isolates were identified by placing with the Gram positive and Gram negative test cards into the Vitec 2 compact device (Biomérieux) in accordance with the procedure.



The antibiogram susceptibility test of the identified bacteria was conducted using by the disc diffusion method explained by Kirby-Bauer.

*Histopathological examination*

For histopathological examination, tissue samples taken from the uterine bifurcation region were determined with 10% formalin and then embedded into paraffin blocks after routine follow-up. Microtome sections with 5µ thickness taken from the prepared paraffin blocks were stained with hematoxylin-eosin according to the procedure and examined by light microscope (Olympus, BX51) (Luna 1968). Degeneration, desquamation, and neutrophil infiltration in lamina epithelialis; neutrophil and mononuclear cell infiltration, connective tissue increase, hyperemia, oedema and haemorrhagie in lamina propria, dilation in endometrial glands, neutrophil infiltration in gland lumen observed in histopathologic examinations were scored and evaluated. Classification of endometritis was carried out histopathologically according to inflammatory changes in the endometrium reported by Hatipoglu et al (2002).

**Results**

The age of the RB cows in the study ranged between three and nine years old. Table 1 shows the distribution of the ages of the RB cows used in the study.

*Macroscopic findings*

In the examination of genital organs of 63 cows after slaughtering, follicular cysts in the ovaries of two RB cows and a cystic structure on the mesovarium of a cow in the control group were observed. After the macroscopic examination, it was determined that the activity continued at least one of the ovaries of all cows.

In one of the examined uterus haemorrhagie in uterine lumen and in the other's uterine mucosa white diffuse and hard small blisters were detected.

Table 1. The age distribution of the cows in the study

Age	Control Group	RB
3	1	1
4	4	11
5	1	14
6	1	14
7	1	8
8	1	2
9	1	3
Total (n)	10	53

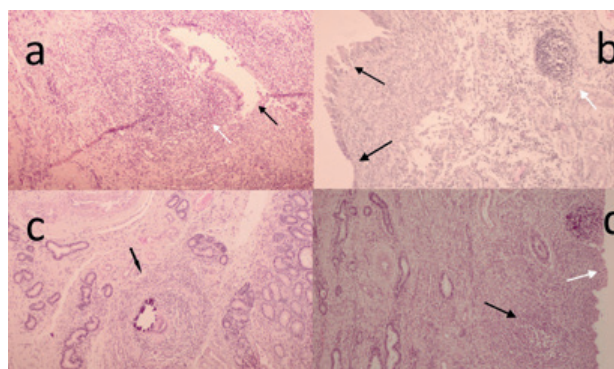


Figure 1. a. Prulent endometritis, degereation and desquamation in epithelial cells (black arrow), neutrophil infiltration (white arrow), (H&E stain, 100x). b. Chronic nonprulent endometritis, degereation and desquamation in epithelial cells (black arrow), mononuclear cells infiltration (white arrow), (H&E stain, 100x). c. Granulomatous endometritis, granuloma in lamina propria and cell aroun infiltration (arrow), (H&E stain, 100x). d. Chronic purulent endometritis, desquamation in epithelial cells (white arrow), neutrophil infiltration (black arrow), (H&E stain, 100x).

Table 2. Classification of endometritis seen in uterus samples as a result of histopathologic examination according to inflammatory lesions

Endometritis Type	RB	Control Group
Catarrhal	5	-
Purulent	5	-
Chronic Purulent	6	-
Chronic Nonpurulent	4	1
Granulomatous	1	-
Total (n)	21	1

*Microscopic findings*

In this study in the histopathologic examination performed, that 22 out 63 uteri were detected endometritis (Figure 1), one of them blonged to control group. The endometritis types are shown in Table 2. Among 41 uteri was no findings of endometritis were found, neither macroscopic nor microscopic findings were observed in 8 uteri, 7 of them belonged to RB cows. The findings of hyperemia, haemorrhagie, oedema, increased number of glands were observed in 33 uteri.

In the macroscopic examination, a small blisters was observed in the lumen and granuloma was detected in the histopathological examination (Figure 1.c.). Table 3 shows the distribution of histopathological and microbiological examination results according to study groups.

*Microbiological findings*

In the microbiological examination, bacteria were isolated in 10 (18.86%) of RB cows and in one (10%) of the control group (Table 4). While one type of bacteria was isolated from 8 of them, 2 types of bacteria were isolated from 3 of them. 5 of the isolated bacteria could not be identified.



Table 3. Distribution of histopathological and microbiological findings obtained from uterus samples

Presence of Endometritis	Group	Inflammation	Connective tissue increase	Degeneration desquamation	Adenomyosis	Edema	Pigment	Dilation in glands	Increase in glands	Microorganism
+	RB	119	111	114	22	99	111	111	55	77
	21	11	11					11		
-	Control			99	88	88	33	112	112	33
	1			22	82	4	11	22	55	11
	RB									
	32									
	Control									
	9									

It was determined that all of the bacteria identified according to the antibiogram result were susceptible to amoxicillin/clavulanic acid and florfenicol and all bacteria except for *Streptococcus* spp. were resistant to penicillin G. Table 5 shows antibiogram results of the identified bacteria.

While in this study endometritis was detected 70% of the bacteria isolated samples in RB cows, was not detected in the control group. Table 6 shows the distribution of the samples isolated from bacteria in terms of endometritis.

## Discussion

Subclinical endometritis is an important factor in the etiology of RB cows, which leads to embryonic deaths and fertilization. The evaluation of clinical and postmortem examination findings with the histopathological and microbiological findings is important in determining the etiology of RB and in developing more appropriate treatment protocols (Dinç 1990, Azawi et al 2008, Ferreira et al 2008, Kaya 2008, Polat 2008, Ergün et al 2009, Cannazik and Polat 2015).

Endometritis is the inflammatory reaction occurs against various factors (parturition, mating, infection, etc.) in the endometrium of uterus. Histopathologically, it is characterized by degeneration, desquamation and inflammatory cell infiltration in the lamina epithelialis, different degrees of inflammatory cell infiltration, vascular, glandular and stromal changes in the lamina propria. (Alaçam 2007, Kaya 2008). However, it is reported that there may be a small number of neutrophils in the endometrium in the prooestrus, oestrus and metoestrus stages in healthy cows and this situation should be considered in the evaluations to be made in the endometrium (Alaçam 2007, Kaya 2008, Espejel and Medrano 2017).

In this study, endometritis was detected in 39% of repeat breeder cows. Other studies reported rates ranging from 12% to 100% (Messier et al 1984, Javed and Khan 1991, Dogan et al 2002, Garoussi et al 2010, Pothmann et al 2015). The reason why endometritis has a very wide range in other studies is thought to be related about the number of selected animals, the difference in management of the enterprises and time.

Table 4. Prevalence of bacteria obtained from the uterus samples as a result of microbiological examination

Microorganism	RB		Control		Total	
	n	%	n	%	n	%
<i>Streptococcus</i> spp.	2	3,77	-	-	2	3,17
<i>Escherichia coli</i>	3	5,66	-	-	3	4,76
<i>Methylobacterium</i> spp.	1	1,88	1	10	2	3,17
<i>Globicetella sulfidifaciens</i>	1	1,88	-	-	1	1,58
<i>Sphingomonas paucimobilis</i>	1	1,88	-	-	1	1,58
Unidentified	4	7,54	1	10	5	7,93



Table 5. Antibiotic susceptibilities of the identified bacteria

Bacteria	Antibiotic Susceptibility								P
	AMC	AMP	TE	GN	SXT	TIL	FFC	ENR	
<i>Streptococcus</i> spp.[1]	S	S	I	I	S	S	S	I	S
<i>Streptococcus</i> spp.[2]	S	S	I	I	S	S	S	I	S
<i>Escherichia coli</i> [1]	S	R	I	S	I	S	S	S	R
<i>Escherichia coli</i> [2]	S	R	I	S	I	S	S	S	R
<i>Escherichia coli</i> [3]	S	R	I	S	I	S	S	S	R
<i>Methylobacterium</i> spp. [1]	S	R	R	S	I	S	S	S	R
<i>Methylobacterium</i> spp. [2]	S	R	R	S	I	S	S	S	R
<i>Globicetella sulfidifaciens</i>	S	I	S	S	S	S	S	S	R
<i>Sphingomonas paucimobilis</i>	S	R	R	S	R	R	S	S	R

S: Susceptible, I: Intermediate, R: Resistant, AMC: Amoxicillin-clavulanic acid, AMP: Ampicillin, TE: Tetracycline, N: Gentamicin, SXT: Trimethoprim-sulfamethoxazole, TIL: Tilmicosin, FFC: Florfenicol, ENR: Enrofloxacin, P: Penicillin G, [ ]: Isolate number.

Table 6. Distribution of the microorganisms in the uterus samples with and without endometritis

	Antibiotic Susceptibility					
	Catarrhal	Purulent	Chronic purulent	Chronic nonpurulent	Granulomatous	Non-endometritis
				1		
<i>Streptococcus</i> spp.	1	2				
<i>Escherichia coli</i>	1					
<i>Methylobacterium</i> spp.			1			2
<i>Globicetella sulfidifaciens</i>				1		
<i>Sphingomonas paucimobilis</i>			1			
Unidentified						4

Haemorrhagic was determined in the lumen of one uterus sample in the macroscopic examination and it was thought in the histopathologic examination that neutrophil infiltration along with mononuclear cell infiltration and increased connective tissue indicated a chronic endometritis and the determined haemorrhagic may be associated with metoestrus.

Degeneration and desquamation at different grades were detected in lamina epithelialis in 25 out of the uterus samples evaluated in the study. Similar findings were determined in cases of endometritis in other studies (Dogan et al 2002, Hatipoglu et al 2002, Azawi et al 2008, Doğruer and Güler 2010). Furthermore, degeneration and desquamation were detected in lamina epithelialis in two of uterus samples of the control group but no inflammatory cells were found in the study. In these two examples, the changes observed in lamina epithelialis are thought to be caused by the errors in the preparation stages.

In the study, increased connective tissues at different grades were observed around the glands in lamina propria of 12

uterus samples. Dogan et al (2002) determined periglandular fibrosis of 13.33% in their study. It was reported that severe periglandular fibrosis may cause embryonic death by inhibiting the glandular functions required by the embryo (Kenney 1978, Polat 2008).

It was thought in the study, the histopathological findings such as hyperemia, haemorrhagic, oedema etc. in the endometrium of 33 (52.34%) uterine samples that is not detected endometritis were the changes based on cycle phase. Dogan et al (2002) stated in their study that they found similar findings in both fertile and RB cows and these were the normal histological changes that did not affect fertility. In addition, it was also reported that the haemorrhagic and stromal oedema in endometrium may result from the estrogenic effects in the follicular phase (Ohtani et al 1993, Espejel and Medrano 2017).

It is stated that depending on its anatomical, histological and functional structure, uterus can be more sensitive to the changes and therefore uterine infections have a significant





negative effect on fertility (Ferreira et al 2008). Physical factors, hormonal effects, humoral and cellular immune mechanisms affect the resistance of uterus against infections (Foster 2007). In the luteal phase where the uterus is under the influence of the progesterone hormone, immunosuppressive substances are secreted to the uterine luminal and this inhibit lymphocyte proliferation and makes the uterus susceptible to many nonspecific bacteria (Milli 1998, Özdemir and Erer 2017).

Genital organ examinations, erroneous artificial insemination practices or natural insemination are the preparatory reasons for the genital canal to be contaminated by bacteria. Elimination of the resistance of uterus against infections increases the production and pathogenicity of bacteria and results in the formation of inflammation in the endometrium. The formed inflammation can affect the viability and motility of spermatozoa, thus preventing the formation of fertilization or causing early embryonic deaths (Rahman et al 1996, Gani et al 2008, Bhat et al 2013).

It was reported in the microbiological examinations conducted with the uterus of repeat breeder animals by Messier et al (1984), Aköz and Dinç (2001), Azawi et al (2008), Gani et al (2008), Ergün et al (2009), Doğruer and Güler (2010), Yılmaz et al (2012), Bhat et al (2013) and Pothmann et al (2015) that *Trueperella pyogenes*, *Escherichia coli*, *Staphylococcus aureus*, *Streptococcus pyogenes*, *Corynebacterium* spp. and *Pseudomonas* spp. were commonly isolated. They reported in the histopathologic examination of the uterus samples of these animals that they detected endometritis at different intensities. It is also stated in the studies that most of these bacteria are isolated from the uterus of fertile cows (Gani et al 2008, Bhat et al 2013).

While bacteria were isolated in 18.86% of the swab samples taken from RB cows in the study. The bacteria isolation rate in swap samples of uterus was reported between the ranges of 52.9 and 75 (Gani et al 2008, Bhat et al 2013, Pothmann et al 2015, Raval et al 2018). The reason why the rate obtained in the present study is lower than the other studies is thought to be associated with the use of antibiotics which samples were taken from cows since the treatment history is not known.

In this study, it was thought that other bacteria, except *Streptococcus* spp. and *Escherichia coli* were nonspecific bacteria and due to their contamination isolated from the uterus. Azawi et al (2008) and Gani et al (2008) suggest that nonspecific uterine bacteria can be transmitted during insemination and when the uterine resistance decreases, their virulence can increase and cause endometritis.

In the study, endometritis were not detected in 3 of the bacteria isolated from uterus specimens and in 15 samples with detected endometritis, the bacteria were not isolated. Yılmaz

et al (2012) reported similar results. Gilbert et al (1998) reported that inflammations in the uterus not related to bacterial infection adversely affect the continuation of the embryonal process.

Raval et al (2018) reported that bacteria isolated against penicillin were resistant to 94.7%, and this rate was 77.7% in our study. It was reported in the previous studies that resistance against penicillin was detected as 50% by Gani et al (2008) and 64.50% by Ergün et al (2009). This increase is thought to be due to unconscious antibiotic use.

### Conclusions

It has been determined that endometritis is major causing factor in the etiology of repeat breeder in cows. Histopathological exams are key to diagnose endometritis causing repeat breeder. It has been concluded that when clinical findings are combined with histopathological and microbiological findings, the effective treatment protocol can be established.

### Acknowledgements

This study was supported by the Selcuk University Scientific Research Projects Coordination Office (Project No: 17202010).

This paper was produced from the Master thesis entitled "Histopathological and microbiological evaluation of uteri in repeat breeder cows sent for slaughtering" of Yunus Çakıcı.

### References

- Ahmed FO, Elsheikh AS, 2014. Treatment of repeat breeding in dairy cows with Lugol's Iodine. IOSR Journal of Agriculture and Veterinary Science, 7, 4, 22-6.
- Aköz M, Dinç DA, 2001. Döl tutmayan (repeat breeder) ineklerde PGF<sub>2α</sub> ve intrauterin köpük sprey (rifaximina) uygulamalarının gebe kalma oranı üzerine etkisinin araştırılması. Hayvancılık Araştırma Dergisi, 11, 2, 51-5.
- Alaçam E, 2005. İnekte infertilite sorunu. In: Evcil hayvanlarda doğum ve infertilite. Eds; Alaçam E, Beşinci Baskı, Medisan Yayınları, Ankara, Türkiye. p. 267-90.
- Alaçam E, 2007. İnekte döl verimi ve sorunları. In: Sığır hastalıkları. Eds; Alaçam E, Şahal M, Üçüncü Baskı, Medisan Yayınevi, Ankara, Türkiye. p. 325-88.
- Azawi OI, Omran SN, Hadad JJ, 2008. A study of endometritis causing repeat breeding of cycling Iraqi buffalo cows. Reprod Domest Anim, 43, 6, 735-43.
- Bhat FA, Bhattacharya HK, Hussain A, Nadeem M, Wani AR, 2013. Microbial profile, antibiogram and conception rate following treatment in repeat breeder cows. Intas Polivet, 14, 1, 42-9.
- Bilgehan H, 1992. Klinik mikrobiyolojik tanı. Fakülteler Kita-





- bevi, Barış Yayınları, İzmir, Türkiye. p. 68-171.
- Cannazik O, Polat B, 2015. İneklerde postpartum dönemde endometritisin sınıflandırılması ve tanımlanmasında kullanılan muayene yöntemleri. Atatürk Üniversitesi Veteriner Bilimleri Dergisi, 10, 3, 198-204.
- Chapwanya A, Meade KG, Doherty ML, Callanan JJ, Mee JF, O'Farrelly C, 2009. Histopathological and molecular evaluation of Holstein-Friesian cows postpartum: toward an improved understanding of uterine innate immunity. *Theriogenology*, 71, 9, 1396-407.
- Diñ DA, 1990. Döl tutmayan (repeat breeder) hayvanlar. In: *Theriogenoloji: Evcil hayvanlarda reproduksiyon, sun'i tohumlama, obstetrik ve infertilite*. Eds; Alaçam E, Nurol Matbaası, Ankara. p. 233-40.
- Dogan I, Sonmez G, Sagirkaya H, 2002. Histopathological investigation of endometrium in repeat breeder cows. *Indian J Anim Sci*, 72, 3, 223-6.
- Doğruer G, Güler M, 2010. İneklerde endometritisin tanısında klinik muayene, endometriyal sitoloji, biyopsi ve mikrobiyolojik muayene bulgularının karşılaştırılması. *Kocatepe Veterinary Journal*, 3, 1, 19-24.
- Ergün Y, Alaçam E, Aydın Y, Seyrek A, 2009. Repeat breeder ineklerde subklinik endometritis rastlantılarının belirlenmesi ve intrauterin sağaltım girişimi. *Lalahan Hayvancılık Araştırma Enstitüsü Dergisi*, 49, 2, 77-89.
- Espejel M, Medrano A, 2017. Histological cyclic endometrial changes in dairy cows: An overview. *Journal of Dairy and Veterinary Sciences*, 2, 1, 1-3.
- Ferreira R, de Oliveira JFC, Antoniazzi AQ, Pimentel CA, Moraes JCF, Henkes LE, Bordignon V, Goncalves PBD, 2008. Relationship between clinical and postmortem evaluation in repeat breeder beef cows. *Cienc Rural*, 38, 4, 1056-60.
- Foster R, 2007. Female reproductive system. In: *Pathologic basis of veterinary disease*. Eds; McGavin M, Zachary J, 4th edition, Penny Rudolph, USA. p. 1263-315.
- Gani MO, Amin MM, Alam MGS, Kayesh MEH, Karim MR, Samad MA, Islam MR, 2008. Bacterial flora associated with repeat breeding and uterine infections in dairy cows. *Bangladesh Journal of Veterinary Medicine*, 6, 1, 79-86.
- Garoussi MT, Sasani F, Hovareshti P, 2010. The histopathological survey of uterine tissue in holstein dairy cows with or without recorded reproductive disorders. *Iranian Journal of Veterinary Science and Technology*, 2, 2, 101-7.
- Gilbert R, Shin S, Guard C, Erb H, 1998. Incidence of endometritis and effects on reproductive performance of dairy cows. *Theriogenology*, 49, 1, 251.
- Hatipoglu F, Ortatatli M, Kiran M, Erer H, Ciftci M, 2002. An abattoir study of genital pathology in cows: II. Uterus, cervix and vagina. *Revue de Médecine Vétérinaire*, 153, 2, 93-100.
- Javed KH, Khan MZ, 1991. Bacteriological and bio-histopathological studies in repeat breeding cows. *Journal of Islamic Academy of Sciences*, 4, 3, 242-3.
- Kaya D, 2008. İneklerde kronik endometritis olgularında Lotagen®, Eucacomp® ve PGF2α uygulamalarının fertilité parametreleri üzerindeki etkilerinin araştırılması. Doktora Tezi, Ankara Üniversitesi Sağlık Bilimleri Enstitüsü, Ankara, Türkiye.
- Kenney R, 1978. Cyclic and pathologic changes of the mare endometrium as detected by biopsy, with a note on early embryonic death. *Journal of the American Veterinary Medical Association*, 172, 3, 241-62.
- Lafi SQ, Kaneene JB, 1988. Risk factors and associated economic effects of the repeat breeder syndrome in dairy cattle. *Veterinary Bulletin*, 58, 891-903.
- Luna LG, 1968. *Manual of histologic staining methods of the Armed Forces Institute of Pathology*. McGraw-Hill, New York, USA. p. 25-77.
- Luperto Telli VA, 2017. Süt sığırı işletmelerinde reproduktif performansın değerlendirilmesi. Doktora Tezi, Ankara Üniversitesi Sağlık Bilimleri Enstitüsü, Ankara.
- Maurer RR, Echterkamp SE, 1985. Repeat-breeder females in beef cattle: Influences and causes. *Journal of Animal Science*, 61, 3, 624-36.
- Messier S, Higgins R, Couture Y, Morin M, 1984. Comparison of swabbing and biopsy for studying the bovine uterus. *Can Vet J*, 25, 7, 283-8.
- Milli Ü, 1998. Dişi genital sistem. In: *Veteriner patoloji cilt II*. Eds; Hazıroğlu R, Milli Ü, Tamer Matbaacılık, Ankara, Türkiye. p. 433-538.
- Ohtani S, Okuda K, Nishimura K, Mohri S, 1993. Histological changes in bovine endometrium during the estrous cycle. *Theriogenology*, 39, 5, 1033-42.
- Özdemir Ö, Erer H, 2017. Dişi genital sistem. In: *Veteriner sistemik patoloji cilt II*. Eds; Erer H, Çiftçi M, İkinci Baskı, Selçuk Üniversitesi Basımevi, Konya, Türkiye. p. 199-20.
- Perez-Marin CC, Moreno LM, Calero GV, 2012. Clinical approach to the repeat breeder cow syndrome. In: *A bird's-eye view of veterinary medicine*. InTech, [cited 12 July 2017]; [337-58]. Available from: <http://www.intechopen.com/books/a-bird-s-eye-view-of-veterinary-medicine/clinical-approach-to-the-repeat-breeder-cow-syndrome>.
- Polat B, 2008. İneklerde postpartum uterus enfeksiyonları. *Atatürk Üniversitesi Veteriner Bilimleri Dergisi*, 3, 3, 56-63.
- Pothmann H, Prunner I, Wagener K, Jaureguiberry M, de la Sota RL, Erber R, Aurich C, Ehling-Schulz M, Drillich M, 2015. The prevalence of subclinical endometritis and intrauterine infections in repeat breeder cows. *Theriogenology*, 83, 8, 1249-53.
- Purohit GN, 2008. Recent developments in the diagnosis and therapy of repeat breeding cows and buffaloes. *CAB Reviews: Perspectives in Agriculture, Veterinary Science, Nutrition and Natural Resources*, 3, 062, 1-34.
- Rahman A, Rahman H, Ahmed MU, 1996. Anestrus and repeat breeding problems in indigenous cattle in Bangladesh. *Tropical animal health and production*, 7, 605-09.
- Raval S, Panchal M, Dhama A, Hadiya K, Bhandari B, 2018. Bacterial isolates and their antibiogram from genital discharges of puerperal and repeat breeding crossbred cows. *Indian Journal of Animal Reproduction*, 39, 58-3.
- Saraswat CS, Purohit GN, 2016. Repeat breeding: Incidence, risk factors and diagnosis in buffaloes. *Asian Pacific Jour-*



nal of Reproduction, 5, 2, 87-95.  
Sheldon IM, Price SB, Cronin J, Gilbert RO, Gadsby JE, 2009. Mechanisms of infertility associated with clinical and subclinical endometritis in high producing dairy cattle. *Reprod Domest Anim*, 44, 3, 1-9.

Yılmaz O, Kuyucuoğlu Y, Sevimli A, Yazıcı E, Uçar M, 2012. Uterine microbiology and histopathology in repeat breeder anatolian water buffaloes: An abattoir study. *Kafkas Univ Vet Fak*, 18, 791-8.

